

Efficacy of Computerized Infrared Imaging Analysis to Evaluate Mammographically Suspicious Lesions

Y. R. Parisky¹
A. Sardi²
R. Hamm³
K. Hughes⁴
L. Esserman⁵
S. Rust⁶
K. Callahan⁷

OBJECTIVE. The purpose of this clinical trial was to determine the efficacy of a dynamic computerized infrared imaging system for distinguishing between benign and malignant lesions in patients undergoing biopsy on the basis of mammographic findings.

SUBJECTS AND METHODS. A 4-year clinical trial was conducted at five institutions using infrared imaging of patients for whom breast biopsy had been recommended. The data from a blinded subject set were obtained in 769 subjects with 875 biopsied lesions resulting in 187 malignant and 688 benign findings. The infrared technique records a series of sequential images that provides an assessment of the infrared information in a mammographically identified area. The suspicious area is localized on the infrared image by the radiologist using mammograms, and an index of suspicion is determined, yielding a negative or positive result.

RESULTS. In the 875 biopsied lesions, the index of suspicion resulted in a 97% sensitivity, a 14% specificity, a 95% negative predictive value, and a 24% positive predictive value. Lesions that were assessed as false-negative by infrared analysis were microcalcifications, so an additional analysis was performed in a subset excluding lesions described only as microcalcification. In this restricted subset of 448 subjects with 479 lesions and 110 malignancies, the index of suspicion resulted in a 99% sensitivity, an 18% specificity, a 99% negative predictive value, and a 27% positive predictive value. Analysis of infrared imaging performance in all 875 biopsied lesions revealed that specificity was statistically improved in dense breast tissue compared with fatty breast tissue.

CONCLUSION. Infrared imaging offers a safe noninvasive procedure that would be valuable as an adjunct to mammography in determining whether a lesion is benign or malignant.

Breast cancer affects one in every eight women in the United States and is ranked second only to lung cancer in cancer-related deaths among women. Randomized controlled trials and large-scale screening programs have shown that periodic screening leads to earlier detection and a reduction in breast cancer mortality [1–4]. Currently, self-examination and regular mammography are the most effective techniques for detecting breast cancer, and it is recommended that women begin undergoing regular screening mammography during their 40s [5, 6]. Mammography, the gold standard screening modality, reveals occult malignant lesions in asymptomatic women at an earlier stage and in smaller lesions, generally producing a more favorable prognosis than is possible by self-examination.

Despite the value of mammography in revealing breast malignancies, most radiographically identified lesions are ultimately found to be benign on histologic assessment after biopsy.

National statistics indicate that between two thirds and four fifths of all breast biopsies have a benign outcome [7–9]. Breast biopsy costs vary considerably, with the expenses ranging from less than a thousand dollars to several thousand dollars [10–12]. Thus, noninvasive methods are needed to aid clinicians in distinguishing benign from malignant breast tissue.

Imaging techniques used in conjunction with mammography and physical examination often include sonography, CT, and MR imaging. Although promising, CT and MR imaging are generally considered too costly for routine use. In addition, MR imaging has not proven to be efficacious in young patients, because MR findings may lead to an unacceptably high number of workups for benign lesions while detecting few malignancies [13]. Sestamibi scintimammography has also been used with varying success to evaluate breast lesions scheduled for biopsy: sensitivities have ranged from 55% to 98%, and specificities have ranged from 79% to

Received January 8, 2002; accepted after revision July 10, 2002.

Supported by Computerized Thermal Imaging, Lake Oswego, OR.

¹USC/Norris Cancer Center, 1441 Eastlake Ave., Los Angeles, CA 90033. Address correspondence to Y. R. Parisky.

²St. Agnes Healthcare, 900 Caton Ave. S., Baltimore, MD 21229.

³Providence Hospital, 1150 Varnum St., N.E., Washington, DC 20017.

⁴Lahey Clinic Northshore, One Essex Center Dr., Peabody, MA 01960.

⁵Mt. Sinai Medical Center, 4306 Alton Rd., Miami, FL 33140.

⁶Battelle, 505 King Ave., Columbus, OH 43201.

⁷Computerized Thermal Imaging, Two Centerpointe Dr., Ste. 450, Lake Oswego, OR 97035.

AJR 2003;180:263–269

0361–803X/03/1801–263

© American Roentgen Ray Society

95% [14–16]. Disadvantages of this technique include the expense, duration of the examination, and patient exposure to ionizing radiation. Sonography is more cost-effective than either CT or MR imaging but has limitations [17–20]. Like mammography, sonography relies on the expertise of the technician and the interpretative skills of the radiologist.

One promising modality for aiding clinicians in differentiating malignant from benign breast lesions is infrared imaging. This modality is noninvasive and detects physiologic tissue response, rather than evaluating anatomic features. As heat is released from the body, a portion is in the form of infrared radiation. Several physiologic features related to malignant tissue may contribute to the infrared signal, including increased blood flow in the area surrounding a malignancy, angiogenesis, and the release of vasoactive mediators [21–26]. The infrared imaging system uses a camera that is highly sensitive to infrared radiation in the appropriate spectrum. This computerized system is designed to show that benign tissue can be differentiated from neoplastic tissue on the basis of the relatively higher strength of the infrared signal in malignant tissue.

In this study, we performed infrared imaging using a computerized dynamic imaging system to capture a series of sequential images of the breast over a short time, which included a period when cool air was blown over the breast. The sequential images were processed using complex proprietary algorithms that assess the infrared information obtained in an identified suspicious area.

The data presented here were collected during a 4-year clinical trial using infrared imaging of patients for whom breast biopsy was recommended on the basis of either clinical or mammographic findings. During the entire course of the study, more than 2400 subjects underwent infrared imaging. The subjects were recruited from five sites that are located in Los Angeles; in Baltimore; in Washington, DC; near Boston; and in Miami. During the initial phases of the study, the subjects' pathology results from biopsies were available to develop the algorithms on which the proprietary analytic software was based.

Subsequent subject data about the biopsy results were collected so that neither the investigational study sponsor nor the evaluating physicians were aware of the outcome, and these data were used to test the efficacy of the infrared imaging system. The results discussed here are from 769 subjects enrolled in this phase of the clinical investigation. During this phase,

the evaluating mammographers used mammograms to localize the suspicious lesion on an infrared image but did not have access to the biopsy outcome. The primary goal was to determine the efficacy of dynamic computerized infrared imaging in enabling clinicians to distinguish benign from malignant lesions. In addition, various breast and lesion features, including breast density, tumor size, and lesion appearance, were evaluated to determine their potential effect on or their correlation to dynamic infrared imaging performance.

Subjects and Methods

Subjects

Recruitment of 1293 subjects who underwent breast biopsy (core or open surgical) for participation in the study was performed at the five investigational sites. Of these 1293 subjects, 769 subjects yielded data that could be evaluated. The study protocol was reviewed and approved by the institutional review boards at each of the five institutions. Breast biopsy was performed because of abnormal mammographic findings, clinical findings, or both. Study exclusion criteria were breast surgery within the past year, breast implants, breast reduction surgery, radiation therapy in the breast of interest, pregnancy, histologically proven cancer in the breast of interest, and weight of more than 300 lb (135 kg) (i.e., the table weight limit). The subjects were enrolled after being provided information about the study and signing informed consent forms that had been approved by the institutional review board at each site.

The original study design required the collection of mammographic data but not of other diagnostic procedures, such as sonography. Mammograms were obtained throughout the clinical trial, and a retrospective review of the mammography reports revealed that sonography had also been performed in approximately 45% of the patients. Thus, the investigators followed standard clinical practice in determining who underwent biopsy. Specifically, the patients whose clinical situation required sonography underwent this examination. However, the sonographic data were not specifically collected and available for use in conjunction with the infrared imaging analysis.

Subject Selection

Of the 1293 enrolled subjects, 524 subjects were excluded from the study for the following reasons. For 229 of the 524 excluded subjects, infrared images were unacceptable because of data file problems; insufficient cooling; or poor image quality caused by excessive patient movement, obstruction of the image by a gown, or poor patient positioning during imaging. The quality of the infrared images was reviewed before the analysis phase of the clinical trial. As site personnel gained experience, the incidence of problems decreased, and infrared images obtained for a separate recently completed clinical

trial of 125 subjects were unacceptable in fewer than 5% of the subjects. In our study, copies of the mammograms were incomplete or unavailable for 209 of the 524 subjects. In addition, 15 subjects were excluded because of other factors including protocol deviations ($n = 9$), inadvertent disclosure of pathology results ($n = 5$), and previous mastectomy ($n = 1$). In all of these cases ($n = 453$), the exclusion of the subject was determined by the evaluating radiologists before the infrared analysis phase and consequently before revealing the pathology data.

As we describe later in this article, each evaluating radiologist used mammograms to locate the lesion on the infrared image using a region of interest. In the remaining 71 excluded cases, either the evaluator could not localize a lesion by a region of interest, which occurred most often in subjects with ambiguous or negative mammographic findings for a palpable mass or in whom the region of interest that was assessed did not correspond to the breast location specified in the case report form by the original physician. We determined that the area localized by the region of interest must correspond within a tightly defined area to the location recorded on the case report form. A significant excursion would likely not evaluate the biopsied area. As illustrated in a representative case, two of the three evaluators localized the lesion in the left breast at the 3-o'clock position, which was consistent with the case report form data (Fig. 1). In contrast, the third evaluator placed the lesion at another location. The exclusions because of this criterion were also made prospectively, before the disclosure of the biopsy results, and were thus not influenced by the pathology outcome. Subjects were excluded in a manner to avoid bias during the analysis phase.

After excluding subjects who could not be evaluated for the study, 875 biopsied lesions in 769 subjects were analyzed for the primary end point of distinguishing benign lesions on the basis of infrared imaging results.

Patient Subsets

In addition to analyzing the total set of 875 lesions, we analyzed a subset of lesions that excluded those described as microcalcifications alone. This restricted subset included 448 subjects with 479 lesions, of which 110 were malignant and 369, benign. We also analyzed the malignant masses from this subset to determine whether the index-of-suspicion value correlated with lesion size.

Data Collection

Subject demographic and study data, including mammographic information, lesion characteristics, infrared and pathology data, were recorded by site personnel on case report forms; all data sources were verified by an independent clinical research organization (Quintiles, Rockville, MD). The site personnel forwarded directly to the study sponsor the data from the case report forms that did not pertain to biopsy outcomes or results. The pages of the case report form that revealed the pathology results were

Infrared Imaging of Suspicious Breast Lesions

collected and maintained separately by Quintiles until all the infrared imaging data were collected and analyzed by the independent evaluators. The evaluators' infrared assessments for all the subjects included in the study were recorded and archived in a secured database before transferring the biopsy results for data analyses purposes.

Infrared Imaging Procedure

The dynamic computerized infrared imaging system (BCS2100; Computerized Thermal Imaging, Ogden, UT) that we used is composed of two independent, but interrelated, functions. To perform the first function, data acquisition, the computerized system collects a series of infrared breast images while the cooled air surrounds the breast. To perform the second function, data analysis, the system analyzes and interprets the infrared data using algorithms that correlate infrared data about the breast being examined to infrared patterns that are associated with either benign or malignant breast tissue. The end result of both functions is a numeric score for a given suspicious lesion after the region-of-interest placement.

Infrared imaging data for each subject in the study were acquired during a single imaging session. The subject lay prone on the imaging bed during the procedure with both breasts suspended through openings in the top of the bed. Each breast was imaged individually while the contralateral breast was shielded from the cooled air by a protective gown. Infrared imaging began with a brief period of temperature stasis, after which a stream of cool air was circulated within the refrigeration chamber around the uncovered suspended breast. Multiple infrared images were obtained in rapid sequence by the infrared camera both before and during the cooling phase. After the first breast was imaged, the process was repeated for the contralateral breast. The entire session required approximately 15 min, with actual imaging time lasting approximately 3 min per breast. The subject's clinical course did not change as a result of undergoing this infrared examination.

Infrared Imaging Assessment

Seven experienced mammographic radiologists who did not participate in the data acquisition phase of the clinical trial were recruited to evaluate the infrared images and determine index-of-suspicion values. Each subject was assigned to three evaluators with a random assignment method using a balanced incomplete block design.

Before beginning each infrared assessment, the evaluator was provided with the subject's mammograms to use for lesion localization on the infrared image. Lesions undergoing evaluation were either directly visible on the mammograms or indicated by radiopaque markers placed on the area of interest. Evaluators were instructed to use the mammograms to localize the lesion on the infrared image, which was displayed as an *en face* image of both breasts (Fig. 1). The six-sided mirror infrared images, an ex-

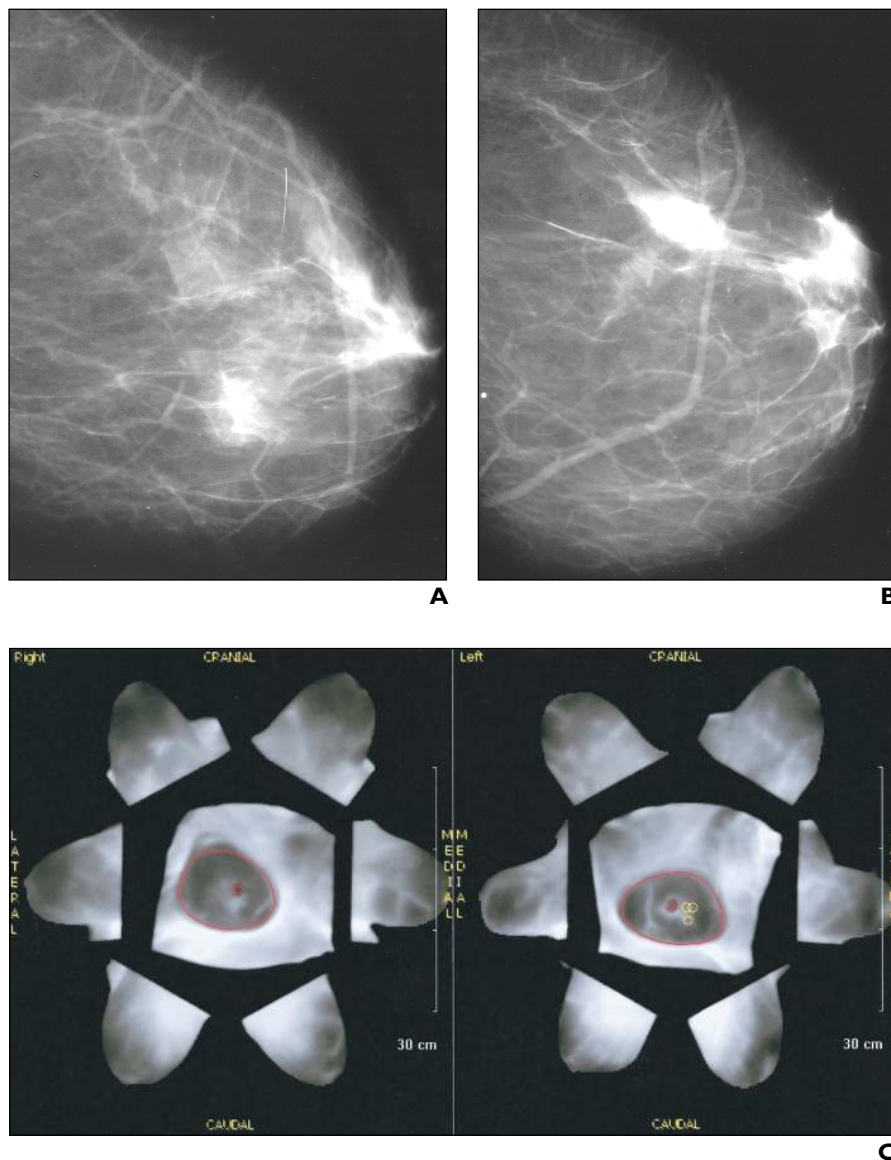


Fig. 1.—67-year-old woman with 2.5-cm asymmetric density in left breast at 3-o'clock position. Note that regions of interest were placed at 3-o'clock position by two of three evaluating radiologists.

A and B, Lateral (**A**) and craniocaudal (**B**) mammograms show suspicious lesion.

C, Infrared image shows *en face* view of each breast. On perimeter are six side-mirror images of each breast. Breast tissue is outlined in red, and regions of interest are outlined in yellow.

ample of which is shown in Figure 1C, could be used to aid in the orientation process. Evaluators used approximately a dozen cases to practice localizing the region of interest; these training sessions required less than 2 hr. In addition, evaluators were provided with the following details about the biopsied lesion: palpable or not; size; quadrant or clock-face location; and six descriptors including mass, spiculation, irregular borders, microcalcification, asymmetric density, and architectural distortion. This information had been recorded at the original site where the patient underwent imaging and was provided to the evaluator to ensure that the lesion undergoing infrared assessment corresponded to the

lesion assessed mammographically and to the lesion biopsied. The evaluators had no knowledge of the pathology outcome for the lesion biopsied.

Evaluators identified the location of the lesion on the infrared image using a region of interest. On the basis of this location, the infrared system assessed a region of interest on the infrared image using a portion (proprietary information) of the breast area surrounding the location identified by the evaluator. An index-of-suspicion value was calculated from the infrared value associated with this selected region of interest.

Not every lesion received three valid interpretations for the following reasons. First, the evaluators were given the option of not completing an infrared

Infrared Imaging Result	No. of Lesions Assessed	Pathology Result
True-positive	482	Malignant
True-negative	260	Benign
False-positive	1544	Benign
False-negative	13	Malignant
Total	2299	

Note.—Each lesion of the 875 lesions was provided to three independent evaluators for assessment; however, some lesions were not evaluated by all three evaluators for reasons discussed in the text.

assessment if they could not localize a suspicious lesion on the mammograms that corresponded with the lesion described in the case report form in terms of its location, type, or both. Second, if an evaluator placed a region of interest that was not within the location defined on the case report form for that lesion, the infrared assessment was not included in the final analysis of imaging results. Excluded assessments were determined before disclosing the pathology data.

Infrared Imaging Results

The index of suspicion represents the likelihood that a given lesion is malignant and yields a numeric value that ranges from 0 to 100. A higher number indicates a higher suspicion of malignancy. The index-of-suspicion scores were recorded as numeric values in a controlled database. A negative or positive result was assigned to each identified lesion on the basis of the index-of-suspicion value using a predetermined threshold. The negative or positive infrared imaging result was assigned before the pathology findings were revealed.

The predetermined threshold was based on a training set of 54 malignant lesions that were used to parametrically model the distribution of index of suspicion. The goal of assessing the training set of malignant lesions was to estimate a threshold that would achieve 99% (138.5/140) sensitivity with the clinical trial data. Sensitivity was used because minimizing the number of false-negatives was considered essential.

Statistical Analysis

The following statistical performance measures were calculated: sensitivity, specificity, negative predictive value, and positive predictive value. Non-parametric methods based on the binomial distributions, bootstrap methods, or both were used to construct confidence intervals (CIs). Because lesions were evaluated one, two, or three times, a weighting procedure was used so that the result for a lesion assessed once was weighted as one, two assessments of a lesion were weighted as one half each, and three assessments were weighted as one third each. This weighting procedure ensured that each lesion was given the same weight in the statistical analysis regardless of how many evaluations were completed.

Patient Information			Lesion ^a	Location		Infrared Imaging Result	
Case No.	Age (yr)	Race		Breast	Quadrant or Position	No. of True-Positives	No. of False-Negatives
1	41	White	A	Right	Upper outer quadrant	0	1
2	42	White	A	Right	Lower inner quadrant	2	1
			B	Right	Beneath the areola	0	3
3	41	Black	B	Right	Upper inner quadrant	1	2
4	42	White	A	Left	Upper outer quadrant	0	3
5	51	White	A	Right	Lower outer quadrant	0	2
6	43	Black	A	Right	9-o'clock position	1	1

Note.—All patients were female. Each lesion was assessed by three independent evaluators.

^aLesions were assigned letter designations when a subject had multiple lesions biopsied.

Results

Of the 769 subjects evaluated, 766 were women and three were men. The racial composition of the study group reflected that of the United States population: white ($n = 463$), black ($n = 207$), Hispanic American ($n = 81$), Asian American ($n = 13$), and others ($n = 5$). The age range of the study subjects extended through all the age categories at risk for breast cancer. Most of the subjects ($n = 433$) were between the ages of 40 and 60 years at the time of infrared imaging. Of the remaining subjects, 68 were younger than 40 years and 268 subjects were older than 60 years. Of the subjects included in the primary efficacy group, 90 had more than one lesion biopsied; most of these subjects ($n = 77$) had two lesions excised. The remaining 13 subjects had more than two lesions biopsied. The total number of evaluated lesions equaled 875. Of these lesions, 187 were malignant and 688 were benign, so 78.6% of the biopsied lesions were benign. This finding is in accord with national statistics [7–9].

The data analysis used the index-of-suspicion threshold to determine whether an index-of-suspicion result was negative or positive for malignancy. The infrared results were established before the pathology outcomes were disclosed. As shown in Table 1, the 875 evaluated lesions resulted in 2299 valid index-of-suspicion determinations by the assigned radiologists. The infrared imaging-based index of suspicion yielded a 97% sensitivity (95% CI, 94–98%) and a negative predictive value of 95% (95% CI, 91–98%). The specificity was 14% (95% CI, 12–16%), and the positive predictive value was 24% (95% CI, 23–24%). It is important to note that all these subjects underwent biopsy because the original site physician characterized a lesion as suspicious, so the

standard clinical workup resulted in a sensitivity of 100% and a specificity of 0%.

The negative predictive value of 95% resulted from evaluators obtaining 13 negative infrared results for seven malignant lesions in six subjects, as shown in Table 2. The interobserver variability among the seven evaluators was as follows: the first evaluator had four of the 13 false-negative results, the second had three false-negatives, the third had two false-negatives, and the remaining four evaluators had one false-negative result each.

Factors that may have contributed to the 13 false-negative findings are as follows. Evaluators may have been confused about the location of the mammographically identified and biopsied lesion, which possibly led to localization of the wrong lesions on the infrared images, because three of the six subjects (cases 1, 2, and 3) had multiple biopsied lesions (lesions were assigned an alphabetic designation as illustrated in Table 2). One of the 41-year-old subjects (case 1) had two additional malignant lesions biopsied, and both of these lesions were correctly evaluated as positive for malignancy by the infrared results. The other 41-year-old subject (case 3) also had three areas biopsied with benign outcomes in lesions A and C. In addition, the evaluators noted that three of the six subjects (cases 1, 3, and 6) appeared to have been poorly positioned during infrared imaging, which also may have adversely affected the outcomes. Finally and perhaps of greatest significance, all the missed lesions were microcalcifications. Pathology findings revealed that four of the seven lesions were ductal carcinoma in situ, whereas two cases were described as ductal carcinoma in situ with stage I focal microinvasion. The one exception was lesion A in case 1, described by

Infrared Imaging of Suspicious Breast Lesions

the physician at the original site as an asymmetric density containing microcalcifications. The pathology result for this lesion indicated intraductal and infiltrating poorly differentiated ductal carcinoma. This case was problematic for a variety of reasons: the subject had multiple lesions, the positioning of the breast for infrared analysis was poor, and a review of this case revealed that the region-of-interest placement was questionable.

Because all the lesions to which evaluators assigned false-negative results were microcalcifications, we analyzed the subset of lesions that excluded those described as microcalcifications alone. This subset consisted of 479 lesions, of which 110 were malignant and 369 benign, in 448 subjects. Table 3 shows the infrared results for this restricted subset. The infrared findings had resulted in a sensitivity and negative predictive value of more than 99% (95% CI, 96–100%) with 291 true-positive results and one false-negative result. The false-negative result in this subset was for case 1 (Table 2), which we described earlier in this article. Although all three evaluators attempted to assess this lesion on infrared imaging, two of the three did not think that the quality of the infrared image was acceptable for analysis. When the same subset was restricted further to include only the cases for which all three evaluators had completed an assessment, the sensitivity and negative predictive value were 100%, the specificity was 19%, and the positive predictive value was 27%.

Table 4 illustrates the distribution of pathology results that were found in the 110 malignant and 369 benign cases. The largest number of malignant results, comprising 68 cases, was in the invasive category: ductal carcinoma alone or ductal carcinoma in combination with other pathology. In the benign category, the most common findings were fibroadenoma and fibrocystic disease, which included 226 cases. These findings accounted for approximately 60% of the benign outcomes. Another 24 cases with benign outcomes were in the high-risk category (i.e., atypical hyperplasia or phyllodes tumor).

Among the features noted during the clinical trial and evaluation phase were breast composition and lesion size. Breast composition appeared to influence the infrared imaging performance. For all 875 lesions, specificity was better for subjects with extremely dense breast tissue than for those with fatty breast tissue (Fig. 2). Infrared results for lesions in breasts with a scattered fibroglandular density and in heterogeneously dense breasts resulted in intermediate specificity values. Sensitivity,

TABLE 3 Infrared Imaging Results for Subset of Biopsied Lesions Excluding Microcalcifications		
Infrared Imaging Result	No. of Lesions Assessed	Pathology Result
True-positive	291	Malignant
True-negative	171	Benign
False-positive	768	Benign
False-negative	1	Malignant
Total	1231	

Note.—Each lesion of the 479 lesions was provided to three independent evaluators for assessment; however, some lesions were not evaluated by all three evaluators for reasons discussed in the text.

which ranged from 94% to 100%, did not appear to be significantly affected by breast density; the lesions with false-negative infrared results described in Table 2 occurred in breasts of scattered fibroglandular density or that were heterogeneously dense). The relationship of breast density and specificity of infrared results became more pronounced when evaluating lesions that were described only as masses. In this subset, which included 412 masses with 90 malignancies, the sensitivity was 100% and the specificity increased from 8% in almost entirely fatty breast tissue, to 15% in scattered fibroglandular tissue, to 20% in heterogeneously dense tissue, and finally to 26% in extremely dense breast tissue. In addition, lesion size of malignant masses correlated well with the index-of-suspicion infrared value (Fig. 3).

Discussion

More than 1 million breast biopsies are performed every year in the United States and approximately 75–80% yield a benign outcome [7–9]. The percentage of breast biopsies with a benign result in this clinical trial (78.6% [688/875 lesions]) was consistent with the national statistic; similar percentages were found among the subsets of lesions analyzed. Mammography is the well-established gold standard for identifying suspicious lesions on the basis of anatomic information. However, as radiologists assess the various ways to improve detection of breast cancer and to better distinguish between benign and malignant suspicious lesions, increasing interest is being focused on the physiologic profile of the disease. Other diagnostic modalities for breast cancer that rely, at least in part, on physiologic processes include sestamibi scintimammography, Doppler sonography, gadolinium-enhanced MR imaging, and positron emission tomography.

TABLE 4 Pathologic Characteristics of 479 Biopsied Lesions Excluding Microcalcifications	
Pathology Result	No. of Cases
Malignant (<i>n</i> = 110 cases)	
Ductal carcinoma alone	34
Ductal carcinoma plus other pathology	34
Lobular carcinoma alone	3
Lobular carcinoma plus other pathology	12
Other invasive types	8
Ductal carcinoma in situ	13
Lobular carcinoma in situ	5
Ductal carcinoma in situ and lobular carcinoma in situ	1
Benign (<i>n</i> = 369 cases)	
Fibroadenoma	124
Fibrocystic characteristics	102
Atypical hyperplasia (ductal or lobular)	22
Lymph node	11
Papilloma	9
Phyllodes tumor	2
Others	99
Total	479

The computerized infrared imaging system that we used was developed to assist physicians in differentiating benign tissue from malignant tissue by characterizing different patterns in the infrared signal emitted by the breast. The infrared imaging system could be used as an adjunct for further evaluating a mammographically apparent breast abnormality when the radiologist has a low-to-moderate suspicion that a malignancy is present. This modality is not designed to be a screening tool for identifying or localizing malignancies or to delay biopsy of highly suspicious lesions. Therefore, a high negative predictive value is essential, whereas the positive predictive value does not have as great a clinical utility.

Although this clinical trial was designed to evaluate the adjunctive value of infrared imaging to mammography, the radiology reports revealed that sonography was also performed in a significant number of patients (approximately 45%). This finding suggests that the infrared imaging assessment would have adjunctive value to standard clinical practice when both mammography and sonography are commonly used in the determination of whether to recommend biopsy.

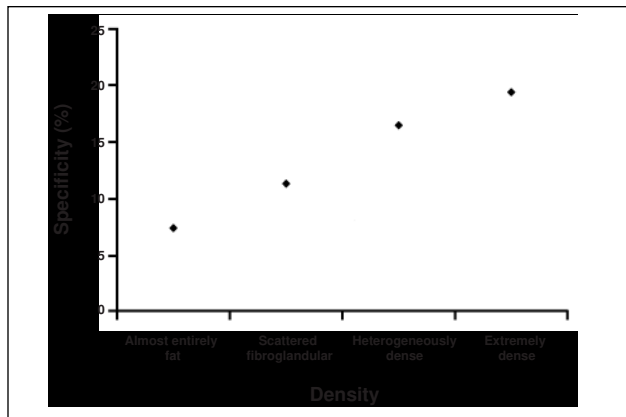


Fig. 2.—Graph shows relationship of specificity to breast density. Density of breast tissue was categorized by evaluating radiologists using mammograms during infrared image assessment. Of 875 lesions evaluated, 55 were found in almost entirely fat breast tissue (sensitivity = 100%); 315 lesions, in scattered fibroglandular breast tissue (sensitivity = 94%); 395 lesions, in heterogeneously dense breast tissue (sensitivity = 98%); 110 lesions, in extremely dense breast tissue (sensitivity = 100%).

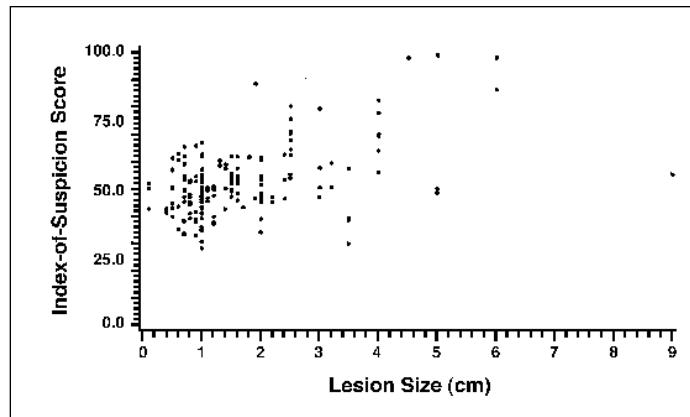


Fig. 3.—Scatterplot shows relationship of lesion size to infrared signal in malignant masses. Note that as lesion size increases, infrared index-of-suspicion score also increases.

Our results suggest that infrared imaging is most efficacious with lesions that are masses. A high negative predictive value was found when assessing these lesions (99%). In contrast, when all the lesions—including those described as microcalcifications—were assessed, the overall negative predictive value was 95%. The malignancies assigned a negative infrared test result by at least one evaluator included seven lesions that contained microcalcifications. Pathologic examination revealed that six of the seven were low-grade ductal carcinoma in situ ($n = 4$) or ductal carcinoma with microinvasion ($n = 2$); the seventh was ductal carcinoma in situ with infiltrating poorly differentiated ductal carcinoma.

Several physiologic factors might explain why infrared imaging did not perform optimally for assessment of ductal carcinoma in situ. A malignant lesion confined to the basement membrane may not substantially influence the physical milieu, whereas a more invasive lesion would. Another factor may be that angiogenesis is less advanced during the earlier stages of ductal carcinoma in situ when the tumor is still sequestered in the duct. Additional studies are needed to address these issues. In our study, we found that most of the lesions containing microcalcifications were correctly determined to be malignant by the infrared imaging procedure.

Of prime importance in assessing the clinical utility of a new modality involved in the diagnosis of breast cancer is the role that the technology might assume in clinical practice. Undergoing breast biopsy of benign tissues places substantial physical and psychologic burdens on the patient without improving patient care. In addition, such

testing has a great economic impact on the health care system [10–12]. Infrared imaging assessment offers a noninvasive, safe procedure that could be helpful in determining whether an immediate biopsy is warranted.

As clinicians acquire experience with infrared technology, they may wish to continue to follow up patients to validate a benign result. One possible scenario is that a negative infrared result for a suspicious lesion could be considered similar to a mammographically detected lesion for which short-interval follow-up is recommended—that is, a BI-RADS (Breast Imaging Reporting and Data System [27]) category 3 lesion. Generally, short-interval follow-up means reassessing the patient by both clinical and radiologic examinations in 3–6 months instead of performing the standard screening annually [27–30]. Factors supporting the value of the short-interval follow-up include lower levels of patient stress, increased subsequent compliance with mammography screening, and lower overall cost [31, 32]. The infrared imaging technology described here is currently being reviewed by the United States Food and Drug Administration, and that agency, as well as clinical experience, will ultimately dictate the appropriate use of this technology.

In summary, infrared imaging holds great promise in the management of breast lesions that can be localized on mammography, either by direct visualization or with commonly used markers. Infrared imaging is an economic and safe modality that provides physiologic data about a lesion. The physiologic view provided by infrared imaging complements the anatomic

view provided by mammography with a very high sensitivity and negative predictive value in masses. Thus, this dynamic computerized infrared imaging system could be a valuable addition to the physicians' armamentarium of diagnostic tools.

References

1. Smart CR, Byrne C, Smith RA, et al. Twenty-year follow-up of the breast cancers diagnosed during the Breast Cancer Detection Project. *CA Cancer J Clin* 1997;47:134–149
2. Tabar L, Fagerberg CJ, Chen HH, et al. Efficacy of breast cancer screening by age: new results from the Swedish Two-County Trial. *Cancer* 1995; 75:2507–2517
3. Fletcher SW, Black W, Harris R, Rimer BK, Shapiro S. Report of the International Workshop on Screening for Breast Cancer. *J Natl Cancer Inst* 1993;85:1644–1656
4. Shapiro S. Screening: assessment of current studies. *Cancer* 1994;74:231–238
5. Leitch AM, Dodd GD, Costanza M, et al. American Cancer Society guidelines for the early detection of breast cancer: update 1997. *CA Cancer J Clin* 1997;47:150–153
6. United States Preventive Services Task Force. *Guide to clinical preventive services*. Baltimore: Williams & Wilkins, 1996
7. Liberman L, Abramson AF, Squires FB, Glassman JR, Morris EA, Dershaw DD. The breast imaging reporting and data system: positive predictive value of mammographic features and final assessment categories. *AJR* 1998;171:35–40
8. Orel SG, Kay N, Reynolds C, Sullivan DC. *Radiology* 1999;211:845–850
9. Liberman L. Clinical management issues in percutaneous core breast biopsy. *Radiol Clin North Am* 2000;38:791–807

Infrared Imaging of Suspicious Breast Lesions

10. Brenner RJ, Sickles EA. Surveillance mammography and stereotactic core breast biopsy for probably benign lesions: a cost comparison analysis. *Acad Radiol* **1997**;4:419–425
11. Burkhardt JH, Sunshine JH. Core-needle and surgical breast biopsy: comparison of three methods of assessing cost. *Radiology* **1999**;212:181–188
12. Bodai BI, Boyd B, Brown L, Wadley H, Zannis VJ, Holzman M. Total cost comparison of 2 biopsy methods for nonpalpable breast lesions. *Am J Manag Care* **2001**;7:527–538
13. Heywang-Kobrunner SH, Schreer I, Dershaw DD. *Diagnostic breast imaging*. New York: Thieme Medical, **1997**:401
14. Clifford EJ, Lugo-Zamudio C. Scintimammography in the diagnosis of breast cancer. *Am J Surg* **1996**;172:483–486
15. Prats E, Aisa F, Abos MD, et al. Mammography and ^{99m}Tc-MIBI scintimammography in suspected breast cancer. *J Nucl Med* **1999**;40:296–301
16. Howarth D, Sillar R, Clark D, Lan L. Technetium-^{99m} sestamibi scintimammography: the influence of histopathological characteristics, lesion size, and the presence of carcinoma in situ in the detection of breast carcinoma. *Eur J Nucl Med* **1999**;26:1475–1481
17. Dixon JM, Walsh J, Paterson D, Chetty U. Colour Doppler ultrasonography studies of benign and malignant breast lesions. *Br J Surg* **1992**;7:259–260
18. Stavros AT, Thickman D, Rapp CL, Dennis MA, Parker SH, Sisney GA. Solid breast nodules: use of sonography to distinguish between benign and malignant lesions. *Radiology* **1995**;196:123–134
19. Bassett LW, Kim CH. Breast imaging: mammography and ultrasonography. *Magn Reson Imaging Clin N Am* **2001**;9:251–271
20. Adler DD, Carson PL, Rubin JM, Quinn-Reid D. Doppler ultrasound color flow imaging in the study of breast cancer: preliminary findings. *Ultrasound Med Biol* **1990**;16:553–559
21. Dixon JM, Walsh J, Paterson D, Chetty U. Colour Doppler ultrasonography studies of benign and malignant breast lesions. *Br J Surg* **1992**;79:259–260
22. Weidner N, Semple SO, Welch WR, Folkman J. Tumor angiogenesis and metastasis: correlation in invasive breast carcinoma. *N Engl J Med* **1991**;324:1–8
23. Gasparini G, Harris AL. Clinical importance of the determination of tumor angiogenesis in breast carcinoma: much more than a new prognostic tool. *J Clin Oncol* **1995**;13:765–782
24. Anbar M. Hyperthermia of the cancerous breast: analysis of mechanism. *Cancer Lett* **1994**;84:23–29
25. Thomsen LL, Miles DW, Happerfield L, Bobrow LG, Knowles RG, Moncada S. Nitric oxide synthase activity in human breast cancer. *Br J Cancer* **1995**;72:41–44
26. Vaupal P, Hockel M. Blood supply, oxygenation status, and metabolic micromilieu of breast cancers: characterization and therapeutic relevance. *Int J Oncol* **2000**;17:869–879
27. American College of Radiology. *Breast imaging reporting and data system (BI-RADS)*, 3rd ed. Reston, VA: American College of Radiology, **1998**
28. Kopans DB. A systematic approach to breast imaging. In: Kopans DB, ed. *Breast imaging*, 2nd ed. Philadelphia: Lippincott-Raven, **1997**:227
29. Sickles EA. Management of probably benign lesions. *Radiol Clin North Am* **1995**;33:1123–1130
30. Sickles EA. Probably benign breast lesions: when should follow-up be recommended and what is the optimal follow-up protocol? *Radiology* **1999**;213:11–14
31. Sickles EA. Successful methods to reduce false-positive mammography interpretations. *Radiol Clin North Am* **2000**;38:693–700
32. Lindfors KK, O'Connor J, Acredolo CR, Liston SE. Short-interval follow-up mammography versus immediate core biopsy of benign breast lesions: assessment of patient stress. *AJR* **1998**;171:55–58
33. McCaul KD, Branstetter AD, Schroeder DM, Glasgow RE. What is the relationship between breast cancer risk and mammography screening? a meta-analytic review. *Health Psychol* **1996**;10:259–267